

## International Journal of Scientific Research and Reviews

### Effect of Detergent on Histology of Fish Intestine

Hooda Vinati and Rathee Radha\*

Deptt. of Zoology, AIJHM - College, Rohtak, Haryana, India  
E-mail: [radharathee@gmail.com](mailto:radharathee@gmail.com), [radha.genetics@mdurohtak.ac.in](mailto:radha.genetics@mdurohtak.ac.in)

#### ABSTRACT

The effect on survival and morpho-histochemical changes in the intestine of young gilthead (fish nursery), *Sparus aurata* induced by acute action of the anionic tensioactive, alkyl benzene sulphonate (ABS) was studied. Anthraquinone dyes damaged the organ directly as a pollutant and indirectly as an agent triggering the proliferation of microbes, which in turn would progressively degenerate different organs responsible for many vital physiological functions. Chronic and sublethal toxicities of cationic surfactant were less than that of other surfactant groups. Chronic toxicity of anionic and non anionic surfactant occurs at concentration greater than 0.1mg/lit. Effects of surfactant on behavioural and physiological parameters range from 0.002-40.0mg/lit.

The LC50 of ABS at 96 hours was found to be 0.6 mg/L with 50 young gilthead exposed to ABS concentrations of 0.5, 1,3 and 5 mg/L, to obtain the surface tension value and exposure time required for 50% mortality of the specimens at each tested concentration. Exposure to ABS caused several forms of histopathological damage in the intestine (destruction of the structure of villi and increase in thickness of the other three layers). Changes in bio-macromolecule components (proteins in general, siderophile proteins, neutral mucopolysaccharides, glycogen and acid mucopolysaccharides) were observed. The degree of these alterations was dependent upon the ABS concentration. These changes could have detrimental effects on the growth and survival of the species. The histopathological study revealed that in intestine tissue destructive changes were directly related to concentration of surfactant dose given to fish and time period of fish exposure to given surfactant.

**KEY WORDS:** Degenerate effect on histology, gilthead, intestinal damage

#### \*Corresponding Author:

Dr. Radha Rathee

AIJHM - College, Rohtak-124001 (Haryana)

E mail - [radharathee@gmail.com](mailto:radharathee@gmail.com)

Ph. No: 9992620108.

## INTRODUCTION:

Detergents are xenobiotic compounds which are usually washed into water bodies and are made up of several compounds of which the active components are the surface active agents or surfactants<sup>1</sup>. It was introduced as biodegradable alternatives to the non-biodegradable branched-chained alkylbenzene sulfonates. The LAS molecules adsorb to the suspended solid in water bodies and hence end up in sediments along the water course or sludge in treatment plants<sup>2</sup>. The recommended LAS that was claimed by some researcher to biodegrade perfectly<sup>3</sup> have also been reported to poorly degrade in rivers, lakes, ponds and even in soils and this may be toxic to aquatic faunas and can also induce severe damage to vital organs and even haematological, hormonal and enzyme disturbances<sup>4,5</sup>. It has also been discovered that detergent surfactant increases microbial populations especially those that are able to use the surfactant as their basic source of carbon or phosphate or both, some of these microorganisms stands as an ectoparasites or endoparasites that causes histological degradation in fish species<sup>6,7</sup>. Xenobiotics compounds concentrate in the tissues of aquatic biotas and are known to produce cumulative deleterious effects<sup>8,9,10</sup>. Therefore, the application of environmental toxicology studies on non-mammalian vertebrates is rapidly expanding for the evaluation of the effects of noxious compounds<sup>11,12</sup>. Indiscriminate discharge of such compounds that contains mixtures of heavy metals such as herbicide, pesticides, detergent etc, their careless handling, accidental spillage or discharged of treated effluents into natural waterways have harmful effects on the fish population and other forms of aquatic life and may contribute long term effects in the environment<sup>13,14,15</sup>. Toxic chemicals cause tissues damage and histopathological degradations as the fish show haematological responses toxicants; and such degradation of histological origin occurs in the intestine and epidermis of animals.

### ***Effect of detergent on intestine of Clarius gariepinus:***

*Clarias gariepinus* is most widely used because it is hardy and able to tolerate both well and poorly oxygenated water. It is widely cultivated in Nigeria water bodies, hence used as biological indicators of ecotoxicological studies. Thus, the aim of this study is to investigate the acute and chronic toxicity of detergent effluent on the African cat fish. This study is based on 45 days exposure of *Clarias batrachus* to sub lethal dose (24.4ppm). Surf, one of the most common household, reflects its toxicological impact on digestive tissue (intestine). Orientation in villi was disturbed and these were disorganized, shortened, flattened and flamed at the base. Tips of villi are ruptured leading to exudation of mucus in lumen. Lamina propria got severe and exhibited oedema. Attachment of mucosal cells with underlying connective tissue got severed making the mucosa to hang freely in the lumen and same were reported by others<sup>16</sup>.

### ***Effect of detergent on intestine of Sparus aurata:***

Effect of the anionic surfactant ABS on gilthead *Sparus aurata* was appropriate because of its importance in the fishing industry and in fish farming<sup>17</sup>. Besides, this species was very sensitive to any fall in the concentration of dissolved oxygen<sup>18</sup>, which make it a useful tool in the study of pollutants that affect the oxygenation of the water. Experimental studies on the fish *S. aurata* shows that detergents has bad effect on digestive of fish such as intestinal tissue- disruption in structure of vill, disruption in the mucosa, sub- mucosa.

### ***Effect of detergent on intestine of Clarius carpio:***

Histopathological study on *C. carpio* exposed to sublethal concentrations of Fenthion was carried out on intestine. The pollutants can affect the animals directly by causing acute to chronic diseases or they could affect the animals indirectly by stressing them. Prevalence of integumental lesions, skeletal anomalies and chromosomal anomalies has been found to be in good association with environmental contamination. Fishes are relatively sensitive to the changes in their surrounding environment. Columnar cells or enterocytes were the more numerous of the epithelial lining cells and closely resemble those of higher vertebrates. These tall and cylindrical cells had striated, free borders (brush border or microvilli) and contained oval nuclei which were situated either centrally or toward the bases of the cells. Intestinal mucous-secreting cells or goblet cells were interspersed among the columnar cells, being more numerous along the sides rather than on the crests or at the bases of the mucosal folds. Intestinal mucous-secreting cells or goblet cells were interspersed among the columnar cells, being more numerous along the sides rather than on the crests or at the bases of the mucosal folds.

### **EFFECT OF DETERGENT ON HISTOLOGY OF INTESTINE-**

The wall of the digestive tract was composed of mucosa, submucosa, muscularis and serosa. Intestinal mucosa was composed of the epithelial layer, the lamina propria and the stratum compactum. Mucosal folds consisted of connective tissue cores covered by intestinal epithelium. These tall and cylindrical cells had striated, free borders (brush border or microvilli) and contained oval nuclei which were situated either centrally or toward the bases of the cells. Intestinal mucous-secreting cells or goblet cells were interspersed among the columnar cells, being more numerous along the sides rather than on the crests or at the bases of the mucosal folds. Goblet cell nuclei were found in the narrow basal portions of the cells. Intestinal goblet cells showed a weak reactivity to PAS, which decreased to very weak after diastase PAS treatment, suggesting the presence of glycogen and neutral mucopolysaccharides. Alcian blue at pH 2.5 showed a weak presence of

carboxylated acidic mucopolysaccharides. Alcian blue at pH 0.4 showed a very weak presence of sulphated, strongly ionize mucopolysaccharides. Toluidine blue 263 revealed metachromasia, indicating the presence of sulphated acidic mucopolysaccharides.

**Lot A (0.5 mg/LABS):** Villi were found to anatomised with each other forming a compact mass and losing their individual outline, while lamina propria could not be discerned clearly. Some areas of epithelium become detached. Submucosa was hypertrophied and muscular layer was thickened.

**Lot B (1 mg/LABS):** Morphological changes are similar to those found at 0.5 mg/L. Intestinal goblet cells: PAS reaction increased slightly respect to control, becoming very weak after enzymatic digestion. Alcian blue (pH 2.5 and pH 0.4) stains also increased slightly respect to control. Toluidine Blue revealed metachromasia.

**Lot C (3 mg/LABS):** There was a complete detachment of epithelium in some areas. Submucosa was infiltrated by lymphocytes.

**Lot D (5 mg/LABS):** Histopathological features were observed pronounced. The whole blocks of epithelia became detached and the mucosal cells were found in a highly disintegrated condition. We observed a more complete destruction of the entire layer. Intestine showed distinct changes after Fenthion treatment. Rupturing of epithelial cells with pycnotic nuclei was the most prominent and revealing feature of tissue damage. Similar observations were made in *T. mossambica* and widow tetra exposed to Thiodan<sup>19,20</sup>. Intestine being an important organ involved in physiological activities of fish, this loss of structural form may cause the death of animal. Being the site of absorption, the gut and intestine are naturally susceptible to the toxic effects of any pollutants entering through either the food or water. The pollutants, primarily affect the tissue leading to dysfunction. In the present study extensive hypertrophy and necrosis was observed in *C. punctatus* exposed to the effluent and similar changes were also reported in other studies<sup>21</sup> in *Heteropneulos fossilis* exposed to textile mill effluents. Someother<sup>22</sup> observed similar effects in *Oreochromis mossambicus* exposed to distillery effluents. The hypertrophy of goblet cells usually results in copious mucus secretion that is a common response of the epithelium to many irritants.

## **RESULTS AND DISCUSSION**

From the above, it is apparent that the test animal of the present study has revealed that the vital organs were damaged at cellular level due to the synergetic effect of pathogenic microbes and disease causing dyes. Thus the present observation strongly recommend for increased scope for

further investigations by including viable pathogens. Acute toxicity of 3 detergents viz. linear alkyl benzene sulfonate. The anionics were found to cause more damage. Triton X-100 affected both the morphology and physiology of the intestine. Triton X-100 also caused the rupture of the intestinal wall and blood vessels. Linear alkyl benzene sulfonate toxicity was reported by other workers<sup>23</sup>. They observed that LAS at 1 ppm caused skin degeneration in rainbow trout. Linear alkyl benzene sulfonate at 1 ppm was also found to cause intestinal damage in *Pisidium casertanum*<sup>24</sup>. Maciorowshi<sup>25</sup> described various histopathological changes in intestine. For this he performed an experiment in which Indian carp (*Cyprinus carpio*) were exposed to Fenthion (0.387, 0.193, 0.096 mg/l) for the period of 60 days. Fishes were sacrificed at the end of the trial period to study light microscopic changes associated with toxicity. Intestines were examined for histopathological studies after the exposure of Fenthion. Many intestinal villi were ruptured near the tips and cellular exudates were also observed. Enlarged mucous cells filled with secretory materials were observed. Proliferations of mucous epithelial cells with pycnotic nuclei were seen.

### ***Intestine control –***

It is a coiled, elongated structure showing following layers.

- i) Serosa (S1); This is the outer most covering consisting of a single layer of epithelial cells.
- ii) Subserosa (S2) or muscularis layer consists of smooth muscle fibers arranged in definite pattern the outer.
- iii) Submucosa (S3); Consisting of connective tissue fibers blood vessels and nerve endings.
- iv) Muscularis mucosa (M1); with two layers of muscles i.e. outer longitudinal and inner circular muscles.
- v) Gastric mucosa (M2); Epithelial coat forming inner layer, formed of columnar prismatic cells with basically located nuclei. The columnar cells of mucosa seem to be modified to form goblet cells which are secretory in function. The entire mucosa was seen folded into number of finger like processes (Figure-1).

Fenthion chronic; (0.387, 0.193, 0.096 mg/ml).

- 1) Epithelial cells of villi show vacuolation.
- 2) Epithelial cells lesions were seen.
- 3) Many villi were ruptured near the tips; cellular exudates were also observed.
- 4) Enlarged mucous cells filled with secretory materials were observed.
- 5) Proliferation of mucous epithelial cells with pycnotic nuclei was seen (Figure-2).

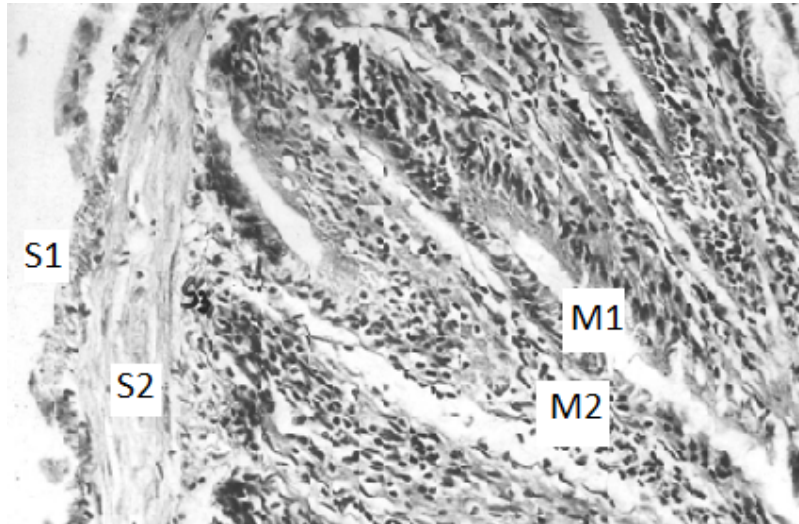


Figure-1. Intestine of control fish showing serosa (s1), subserosa (s2), submucosa (s3), muscularis mucosa (m1) and gastric mucosa (m2).

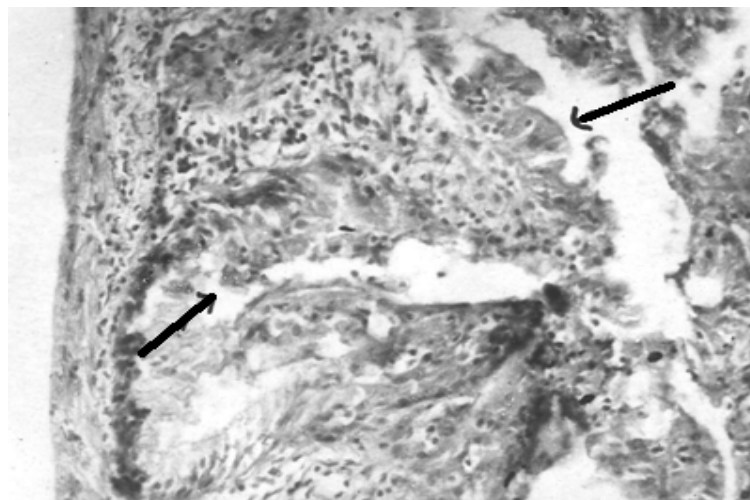


Figure-2. Intestine of fish exposed to 0.38mg/lit. Fenthion showing epithelial cell lesion, shrunken and extremely damaged villi.

Surf exposed fish intestine revealed severe atrophic degeneration. The mucosa lost its usual shape and normal architectural plan. Villi revealed altered orientation and were disorganized greatly reduced, flattened and inflamed at base. Their tips were found ruptured at places leading to the exudation intestinal mucus in lumen. The nuclei were disintegrating and occupied apical position contrary to the basal one in control. Lamina propria became reduced and their cells with the underlying connective tissue were severed due to which mucosa hanged freely in the lumen. Litreture<sup>26</sup> reported vacuolization of columnar epithelial cells, extremely reduced villi and

exudation of mucus in lumen in the intestine malathion and bhc treated of punctius sarana. Similar observations have also been made under methionate exposure in *Cyprinus carpio* in *Channa punctatus* under influence of aquatic pollutants (detergents)<sup>27,28</sup>. Rupture of tips of villi observation in the present case may be regarded as a mode of detoxification to get rid of intestine; as suggested<sup>29</sup>. Other cellular injuries including oedema may be associated with the release of acid hydrolases from lysosomes leading to the autolysis of cell. Damages inflicted in mucosa, more especially the villi are of special concern since villus is the working unit of intestine and it is the villi that the inner ends of absorptive cells come in contact with blood and lymph which pick up absorbed nutrient to carry them to other parts of body. The function of villi is so significant and damages at this site in the present case being so severe the extent of disturbances in the intestine can be easily be thought to be due to detergents. It appears that surf has blocked the paracellular pathways which are created at the junctions between intestinal cells for movement of ions and similar water soluble to lamina propia<sup>16</sup>.<sup>30</sup>. Maciorowski<sup>25</sup> also reported that the effect of anionic surfactant on intestinal damage to clams was reversible. Physiological effect concentration of anionic detergents on species of fish ranges from 0.54 and > 1.56mg/lit for alkyl ethoxylates.

## **CONCLUSION**

It was concluded that anionic detergents has more toxicity results in several fish species than cationic detergents. Alkyl sulphates (anionic), alkyl ethoxylate sulphate (anionic) and several monoalkyl and dialkyl quaternary ammonium salts (cationic) effects fish when treated with surfactant having these compounds.

## **REFERENCES:**

1. Abbas H H, and Mahmood H M. The toxicological effect of water pollution on the Nile Tilapia fish (*Oreochromis niloticus*) collected from four sites along the River Nile. J Egypt Vet Med Assoc. 2003; 63:307-323.
2. Abbas H H, and Mahmood H M. Haematological and biochemical changes in *Oreochromis aureus* and *Clarias gariepinus* exposed to mixtures of copper and lead salts. Egypt J Basic Appl Physiol. 2004; 3: 89-106.
3. Adewoye and Lateef A. Evaluation of the microbiological characteristics of Oyun river – A polluted river in North-central Nigeria. Pollution Res. 2004; 23(14): 587–591.
4. Adewoye SO, Fawole OO, Owolabi OD, and Omotosho JS. Toxicity of cassava wastewater effluents to African catfish: *Clarias gariepinus*. Ethiop J Sci. 2005; 28 (7): 189-194.

5. Aguiwo J N. The toxic effects of cymbush pesticides on growth and survival of African catfish, *Clarias gariepinus*. *J Aquat Sci.* 2002; 17(2): 81-84.
6. Ayoola S O. Histopathological Effects of Glyphosate on juvenile African Catfish (*Clarias gariepinus*) Ameri-surasian. *J Agric & Environ Sci.* 2008a; 4 (3): 362-367.
7. Ayoola S O. Toxicity of Glyphosate herbicides on Nile tilapia (*Oreochromis niloticus*) juvenile. *Afric J Agric Res.* 2008b; 3 (12): 825- 834.
8. Cavalli L, Cassani G, Pravettoni S, Nucci O, Larrizarin M, Zatta A, and Vigano L. Surfactants in Sediments. *CLER Review.* 2000; 6 (1): 32-43.
9. Eniola KIT, and Olayemi AB. Some Aspects of Bacterial-Detergents interaction in fresh water environment. *Bioscience Research communication.* 2002; 14(6): 645-649.
10. Ogundiran MA, Fawole OO, Adewoye SO, and Ayandiran TA. Toxicological impact of detergent effluent on juvenile of African Catfish. *Agric Biol J N Am.* 2010; 1(3): 330-342.
11. WHO – World Health Organization. International programme on chemical safety environment health criteria 169 Linear Alkylbenzene Sulfonates and related compounds. World Health Organization Geneva.1996.
12. Ogundiran M A, Fawole O O, and Adewoye S O. Effects of Soap and Detergent Effluents on the Haematological Profiles of *Clarias gariepinus*. *Science focus.* 2007; 12(1): 84-88.
13. Ogundiran MA, Fawole OO, Adewoye SO, and Ayandiran T A. Pathologic Lesions in the Gills Structures of *Clarias gariepinus* on exposure to sub lethal concentrations of soap and detergent effluents. *J Cell and Animal Biol.* 2009; 3 (5): 78-82.
14. Olojo E A A, Olurin K B, Mbaka G, and Oluwemimo A D. Histopathology of gills and liver tissues of the African catfish *Clarias gariepinus* exposed to lead. *Afr J of Biotech.* 2005; 4 (1): 117-122.
15. Omoniyi I, Agbon A, and Sodunk SA. Effects of lethal and sub-lethal concentrations of tobacco (*Nicotiana tobaccum*), leaf dust extract on weight and haematological changes in *Clarias gariepinus*. *J Appl Environ Man.* 2002; 6: 37-41.
16. Van Dyk GM, Pieterse JHJ, and Vuren M. Histological changes in the liver of *Oreochromis mossambicus* (Cichlidae) after exposure to Cadmium and zinc. *A review of Ecotoxicology and Environmental Safety.* 2005; 2 (1): 1-9.
17. Srivastava A K, and Srivastava A K. Review of investigations on biological effects of Selenium on fish. *J Freshwat Biol.* 1994; 6(4): 285-293.
18. Lightowlers P. Still dirty: A review of action against toxic products in Europe. A report for WWF-UK; 2004.



19. Malik R, and Hodgson H. The relationship between the thyroid gland and the liver. *Quart J Med.* 2002; 95:559-569.
20. Mcavoy D C, Eckhoff W S, and Rapaport R A. The fate of Linear alkylbenzene sulfonates in the environment. *The Clear Review.* 1997; 3(1):4-7.
21. Myers M S, Johnson L L, Olson O P, Sther C M, Homess B H, Collier T K, and McCain B B. Toxicopathic hepatic lesions as biomarker of chemical contaminants exposure and effects in marine bottomfish species from the northesther and Pacific Coast. *USA Mar Pollut Bull.* 1998; 37: 92-113.
22. Odiete WO. Impacts associated with water pollution. In: *Environmental Physiology of Animals and Pollution.* 1st Edition. Diversified Resources Ltd, Lagos Nigeria; 1999; 187–219.
23. Geetanjali C, and B S. Jhainfluence of the household detergents on some serum biochemical parameters of freshwater fish channa punctatus. *The Bioscan.* 2013; 8(4):1343-1345.
24. Kamble S M, and Tapale B K. Effect of sublethal concentrations of a household detergent on certain biochemical constituents of catfish, *Mystus seenghala.* *Biosci Biotech Res Comm.* 2011; 4:198-204.
25. Maciorowski A F, Dolan J M. and Gregg B C. Histological damage and recovery of *Pisidium castor-tanum* exposed to linear tridecyl benzene sulfonate, and anionic surfactant. *Comp Biochem Physiol.* 1997; 56: 117-122.
26. Ogochukwu NH and Joseph CI. Toxicity of crude oil product and detergent on serum alkaline phosphatase concentration of *Clarias gariepinus* juveniles. *Animal Research International.* 2009; 6:1045-1048.
27. Ogundiran M A, Fawole O O, Adewoye S O, and Ayandiran TA. Toxicological impact of detergent effluent on juvenile of African catfish (*Clarias gariepinus*) (Buchell 1822). *Agric Biol J N Am.* 2010; 1:330-342.
28. Reid S G, Bernier N J, and Perry S F. The adrenergic stress response in fish: Control of catecholamine storage and release. *Comp Biochem Physiol.* 1998; 120: 1-27.
29. Summarwar S and Lall D. 2013. Effect of toxins on blood plasma of *Clarias batrachus.* *Indian J Fundamental and Applied Life Sciences.* 2013; 3:133-136.
30. Travlos G S, Morris R W, Elewell M R, Duke A, Rosenblum S, and Thompson M B. Frequency and relationship of clinical chemistry and liver and kidney histopathology finding in 13 week toxicity study in rats. *Toxicology.* 1996; 107: 17-29.